

DOI 10.24425/119036

Original article

Therapeutic activity of chlorhexidine-poloxamer antiseptic gel on wound healing in rats: a preclinical study

L. Babickaite¹, A. Grigonis¹, K. Ramanauskienė², A.P. Matusėvičius¹,
G. Zamokas¹, G. Daunoras¹, M. Ivaškiene¹

¹ Lithuanian University of Health Sciences, Veterinary Academy, Faculty of Veterinary Medicine,
Tilzes 18, 47181 Kaunas, Lithuania

² Lithuanian University of Health Sciences, Medical Academy, Faculty of Pharmacy,
Department of Clinical Pharmacy, Sukileliu av. 13, 50009 Kaunas, Lithuania

Abstrakt

Despite the progress in curative and preventive medicine, skin lesions after injuries or surgical interventions are still a big problem. The aim of wound care is to get damaged tissues to heal as soon as possible. A gel-forming material helps to maintain proper humidity in the wound and promotes the healing process. For this purpose, a healing gel containing the active substance chlorhexidine based on poloxamer was prepared. The aim of this study was to assess *in vivo* the therapeutic efficacy of chlorhexidine-poloxamer gel in treatment of wounds caused experimentally and inoculated with bacteria, and the effect of an antiseptic gel applied on a healthy rat skin. Wistar albino rats were selected for these studies. The effect of an antiseptic gel on the healing excision and incision wounds, as well as the irritating effect on the healthy skin were assessed. Cross-sectional full-thickness specimens from each group were collected at the end of the experiment to assess the histopathological alterations. Chlorhexidine-poloxamer gels accelerate the healing of infected skin wounds because the active ingredient chlorhexidine remains at the application site, and systemic effects are avoided. Moreover, chlorhexidine-poloxamer gels are easy to use because they can be easily washed off from the wound surface by water. The present study has revealed that chlorhexidine-poloxamer gels promote healing of full-thickness skin wounds without skin irritation. This makes it possible to plan further clinical trials in the target species.

Key words: skin, wound, chlorhexidine, poloxamer, healing, gel

Introduction

Only healthy skin forms a protective barrier against harmful environment factors. In the case of surgery and/or trauma the skin is damaged

(Sabol et al. 2012). When skin is damaged, tissue fluid is released and intense proliferation of permanent and transient microorganisms begins. Local infection in damaged tissues begins two hours later (about 40% of pathogens isolated from infected surgical sites is

Staphylococcus aureus). If damaged skin comes into contact with environmental surfaces, microorganisms from those surfaces infect the damaged tissue too. The healing process gets worse and slows down (Acompara et al. 2006). The presence of foreign material increases the risk of infections; specifically, surgical sutures can act as a wick for suture-associated infection. So pathogens from natural skin flora can easily enter wounds via capillary action leading to chronic infections (Obermeier et al. 2014). Once a suture is in contact with the wound, its threads are quickly coated with proteins-rich fluids, like fibrinogen and fibronectin, which create the ideal environment for the proliferation of microorganisms in damaged skin (Scaffaro et al. 2013); sutures irritate the skin and the wound, which promotes the start of an infectious process. However, when the wound is sutured, migration of microorganisms to the wound is significantly reduced and only local infectious process occurs (Acompara et al. 2006).

Despite progress in curative and preventive of medicine, skin lesions after injuries or surgical interventions are still a big problem. The aim of wound care is to get damaged tissues to heal as soon as possible. Contact with air often leads to dehydration of the wound and the amount of nutrients needed to form new tissues and white blood cells decreases, which slows down the wound healing rate. Topically used drugs have to maintain a moist wound environment that helps the wound heal faster. Animal fat-based ointments and creams containing antimicrobials are often used for healing of wounds. These ointments or creams are well absorbed into deeper tissues, and antimicrobials, which are components of these products, negatively affect the quality of meat and milk. If antimicrobials in the ointment are less effective against one or another species of microorganisms, the latter develops resistance. Therefore, the base of ointments, creams or gels has to inhibit resorption of active chemical substances, then the effect would be seen in the wound only. Antiseptic substances are often chosen for this purpose, they are also often chosen in a form of gels, which protect the wound against bacterial infection and destroys microflora which enters the wound. A gel-forming material helps to maintain proper humidity in the wound and promotes the healing of wounds (Jiang et al. 2012). For this purpose, a healing gel containing the active substance chlorhexidine and based on a poloxamer was prepared.

Chlorhexidine, a bisbiguanide antiseptic, has excellent efficacy against gram-positive bacteria, although its efficacy against gram-negative bacteria is less pronounced (Banovic et al. 2013). Chlorhexidine is characterized by its strong binding to the skin, and

ability to adsorb to negatively charged surfaces. Depending on the concentration, all vegetative bacterial forms either are quickly and completely destroyed, or their growth is inhibited due contact with an antiseptic. Chlorhexidine does not allow bacterial spores to overgrow (Salami et al. 2006). Chlorhexidine exerts its major antibacterial effects by interfering with the function of cellular membranes, the primary site of action being the cytoplasmic membrane. Binding of biguanide groups to phospholipids in the membrane induces structural modifications, with leakage of the intracellular components. Some efficacy studies have demonstrated that chlorhexidine induces a more significant reduction of bacterial cultures than other antimicrobial compounds. Chlorhexidine exerts its major antibacterial effects by interfering with the function of cellular membranes. A binding of biguanide groups to phospholipids in the membrane induces structural modifications to a bacterial surface, and the changes of the bacterial wall membrane and osmotic balance due to lipophilic groups of an antiseptic. Chlorhexidine inhibits the activity of enzymes and disturbs the transportation of potassium ions, nucleotides, and amino acids through a cell membrane. Chlorhexidine is widely used in veterinary medicine for its broad antimicrobial activity and low toxicity (Odore et al. 2000, Banovic et al. 2013, Babickaitė et al. 2016).

Poloxamers have gained increasing attention due to their abilities in repairing biological membranes damaged by trauma and diseases (Dumortier et al. 2006). A poloxamer 407 stimulates the immune response, cell proliferation, fat metabolism, collagen synthesis, tissue microcirculation. A poloxamer used topically maintains the stability of a number of water-soluble medicinal substances. The gel provides not only a non-toxic detergent cover to the wound, but specific studies suggest that the gel itself may also have a beneficial action, accelerating healing of wounds. Studies have shown that a poloxamer has immunomodulatory properties and inhibits the activation of neutrophils (Dumortier et al. 2006, Patel et al. 2009). This medical substance is attractive because it is transformed from a low-viscosity solution at low temperature to a semisolid gel at higher temperature (Patel et al. 2009). A poloxamer gel shows temperature-dependent gelation (gel consistency at 37°C and liquid consistency at 4°C) (Carceles et al. 2006, Babickaitė et al. 2016). Previous studies have shown (Babickaitė et al. 2016) that a chlorhexidine-poloxamer gel is effective against gram-positive and gram-negative reference and wild type bacteria *in vitro*.

Aim of this study was to assess *in vivo* the therapeutic efficacy of a chlorhexidine-poloxamer gel in

Table 1. Composition of chlorhexidine digluconate gels.

Concentration of the chlorhexidine-poloxamer gel	Composition, %		
	20% chlorhexidine digluconate aqueous solution	Poloxamer 407	Purified water
0.25%	1.25	25	73.75
0.5%	2.5	25	72.5
1.0%	5.0	25	70.0

treatment of wounds caused experimentally and inoculated with bacteria, and the effect of an antiseptic gel applied on healthy rat skin. The rat was the experimental animal of choice due to factors such as easy obtention, handling and maintenance. Another advantage in the use of rats is the smaller amount of elastic fibers on the corium, which allows to study intense or less intense processes depending on the antiseptic agent involved. However, the entire process of healing is not a mirror reflection of that in human or other mammalian wounds because a vivid hypertrophic scar or keloid are not formed in rats. Also there are a lot of sweat (sebaceous) glands and hair follicles in the rat skin, which lead to a very fast and intense period of epithelisation (Acompara et al. 2006).

Materials and Methods

A chlorhexidine-poloxamer gel. The investigated antiseptic gel was composed of chlorhexidine, poloxamer 407 and water (Table 1). Twenty percent chlorhexidine digluconate aqueous solution was added to the purified water. A poloxamer 407 (polyoxyethylene-polyoxypropylene-polyoxyethylene polymer) was added to the above mixing it slowly. A compound was kept in a refrigerator at temperature +4°C until dissolved. Hydrogels were formed by solidifying when the compound was kept at room temperature.

Animals. Wistar albino rats (222 ± 29 g) were selected for these studies (study protocol was approved by State Food and Veterinary Service (permission No. 6)). They were kept individually on sawdust litter and at 24 ± 2°C, humidity 50-60%, a 12 h light/dark cycle. Throughout the experiment the rats were maintained on standard pellet diet and water *ad libitum*. The animals were left for 5 days at 20-22°C for acclimatization. The rats were weighted prior to the surgical procedure and during the experiment once a day. They were anaesthetized prior to the creation of wounds using intramuscular injected ketamine hydrochloride (Bioketan 10%, Vetoquinol, Poland; 50 mg/kg body weight) and diazepam

(Apaurin 0.5%, Krka, Slovenia; 1 mg/kg body weight). Local anaesthesia was achieved using 2-3 ml 0.5% lidocaine (Lidocaine Grindeks, Latvia) by infiltration/wired application method.

In each experiment the animals were divided into 5 groups with 5 rats in each group: wounds in the I group were treated with a poloxamer, wounds in the II group were treated with a 0.25% chlorhexidine-poloxamer gel, wounds in the III group were treated with a 0.5% chlorhexidine-poloxamer gel, wounds in the IV group were treated with a 1% chlorhexidine-poloxamer gel, wounds in the V group were untreated (a control group).

Excision wound model (Akilanderesnari et al. 2010). The animals were anaesthetized and the back hair was shaved using shaving machine, the skin was cleaned with 70% ethanol solution. One excision wound was inflicted by cutting away 200 mm² full thickness of skin from the depilated area, the wound was left undressed to open environment. In this experiment, 0.1 ml of 0.5 McF *S. aureus* (ATCC 25923) was used as a standard strain for the wound inoculation. The gels were applied once daily (10 mg) till the wound was completely healed. This model was used to monitor wound contraction and wound closure time. Wound contraction (%) was calculated once a day using the following formula (Selvaraj et al. 2011):

$$\% \text{ wound area} = \frac{\text{Wound area in the day X}}{\text{Wound area in the first day}} \times 100$$

$$\text{Percentage of wound healing} = 100 - \text{percentage of wound area}$$

Sutured wound model (Nayak 2007). The rats were anaesthetized and the back hair was shaved using shaving machine, the skin was cleaned with 70% ethanol solution. One full-thickness incision of skin was made. In this study, wounds were infected with the standardized 0.1 ml of 0.5 McF *S. aureus* (ATCC 25923), 15 minutes after the incision was made, the parted skin was kept together and stitched with surgical threads (Chiraflon 3/0, Chirmax, Czech).

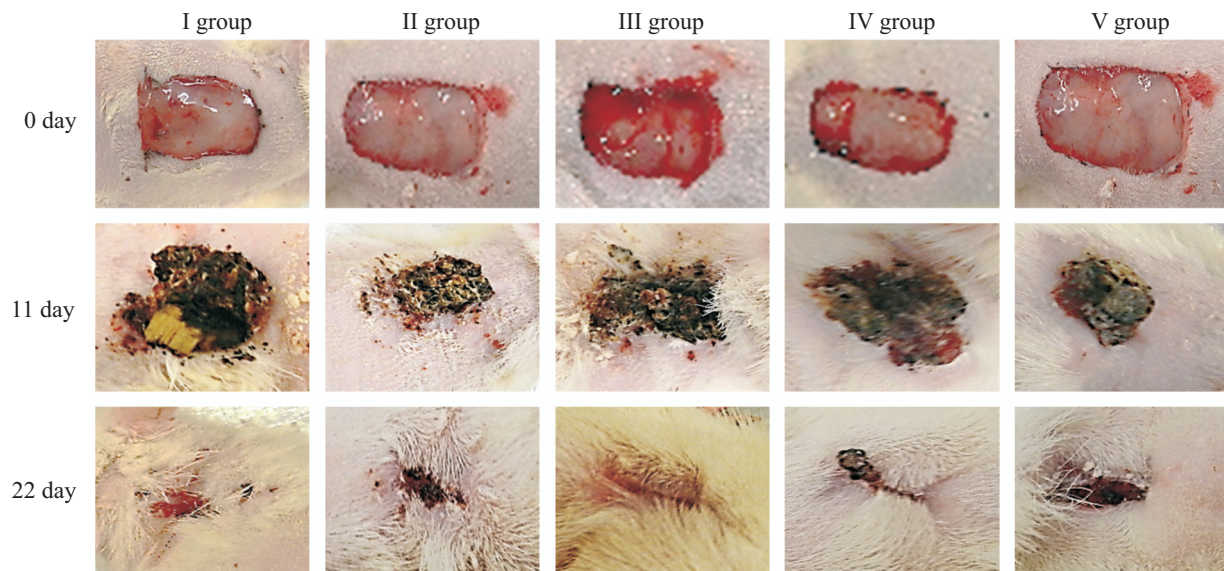


Fig. 1. Healing of wounds after application of different concentrations of an antiseptic gel.

Note: I group – wounds treated with poloxamer, II group – wounds treated with 0.25% chlorhexidine-poloxamer gel, III group – wounds treated with 0.5% chlorhexidine-poloxamer gel, IV group – wounds treated with 1% chlorhexidine-poloxamer gel, V group – untreated wounds.

This model was used to monitor thickness of skin, inflammation and infection signs.

Skin irritation. The animals were anaesthetized and the back hair was shaved using shaving machine, skin cleaned with 70% ethanol solution. The gels were applied once daily (10 mg) 10 days. The animals were observed once a day. Skin-fold thickness, skin redness, itching, edema, tremors, convulsions, salivation, diarrhoea, lethargy, sleep behavioural and clinical abnormalities were assessed.

Histopathological investigation. The rats were euthanized after a complete healing of the full thickness wounds and after a skin irritation test (Dolethal 20%, (Vetoquinol S.A., France, 150 mg/kg i.v.). The cross-sectional full-thickness specimens from each group were collected at the end of the experiment to assess the histopathological alterations. Skin biopsy was performed by cutting skin with surrounding tissues to the fascia including muscle *panniculus carnosus*. Samples were fixed in 10% buffered formalin, processed and blocked with paraffin and then sectioned at 5 μ m and stained with haematoxylin and eosin. The following parameters were considered for the microscopic assessment: reconstruction of epidermis and dermis (reepithelisation, fibroblast proliferation, mononuclear and/or polymorph nuclear cells, formation of granulation tissue) (Oryan et al. 2010). The thickness of the epidermis (*stratum basale*, *stratum spinosum*, *stratum granulosum* and *stratum lucidum*) was also measured. *Stratum corneum* was not included. Measurements were performed in 8 different locations of a sample.

Results

During the experiment no animals died. Rats were active, adequately responded to the environment during the experiment. Water and food consumption did not change, porphyrins around the eyes were not found.

Excision wound model. A complete epithelisation of full-thickness skin wounds was considered as the end point of the experiment. The area of mechanically created wounds increased after excision by an average of 337.9 ± 26.0 mm². The speed of wound healing was not equal when different concentrations of the chlorhexidine-poloxamer gel were used (Fig. 1). Signs of infection were not determined in rats of the experimental groups (II-IV groups). The presence of infection on the skin adjacent to the incision, with the presence of purulent plaque and fetid odour, was observed on the 2nd postoperative day in animals of I and V groups, suggesting pyodermatitis. Signs of infection in the area of wounds were not observed on the 4th day of the experiment.

Using 0.25% chlorhexidine-poloxamer gel, the area of full-thickness skin wounds decreased by an average of 15.1 ± 17.2 mm² per day. On the 10th day, the average wound area was 73.7% smaller than that on the 1st day of the experiment or 2.3% smaller than that in rats of the I group, and 23% smaller than that in rats of the V group ($p < 0.05$). On the 20th day, the average wound area was 24.6% smaller than that on 10th day and 98.3% smaller than that on the 1st day of the experiment. On the 20th day of the experiment,

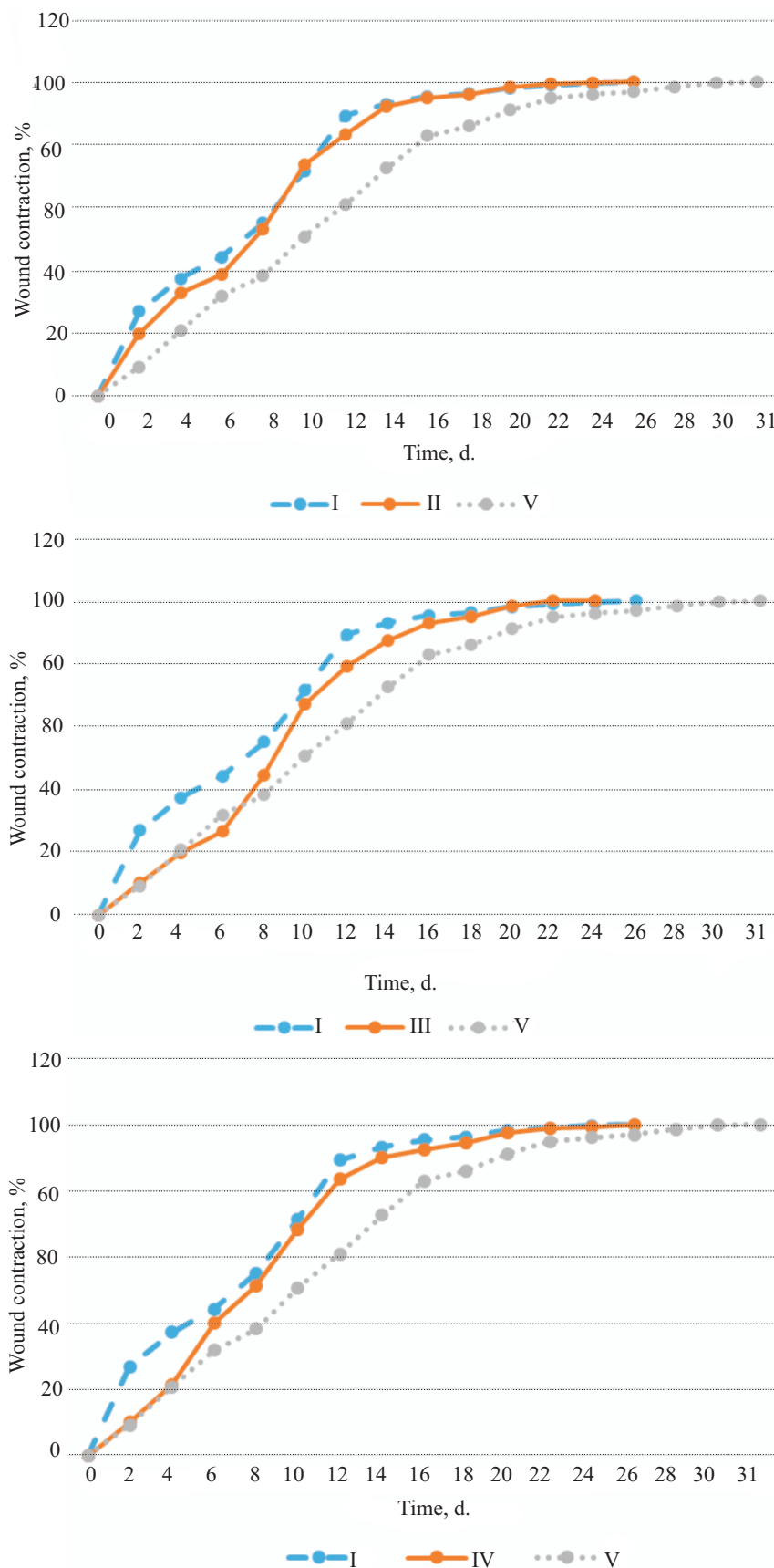


Fig. 2. Wound healing rate after application of different concentrations of chlorhexidine-poloxamer gel. (I group – wounds treated with poloxamer, II group – wounds treated with 0.25% chlorhexidine-poloxamer gel, III group – wounds treated with 0.5% chlorhexidine-poloxamer gel, IV group – wounds treated with 1% chlorhexidine-poloxamer gel, V group – untreated wounds).

the average wound area in rats of the II group was 0.1% smaller than that in rats of the I group and 7.2% smaller than that in rats of the V group ($p < 0.05$) (Fig. 2). The complete epithelisation of wounds in the rats of the II group was seen on 25th day of the experiment.

Using 0.5% chlorhexidine-poloxamer gel, the area of full-thickness skin wounds decreased by an average of $14.6 \pm 11.9 \text{ mm}^2$ per day. On the 10th day the average wound area was 67.0% smaller than that on the 1st day of the experiment or 4.4% larger than that in the rats of the I group and 16.3% smaller than that in rats of the V group ($p < 0.05$). On the 20th day, the average wound area was 31.0% smaller than that on 10th day and 98.3% smaller than that on the 1st day of the experiment. On the 20th day of the experiment, the average wound area in rats of III group was 0.1% smaller than that in rats of the I group, and 7.2% larger than that in rats of the V group ($p < 0.05$) (Fig. 2). Complete epithelisation of wounds in rats of the III group was observed on 22th day of the experiment.

Using a 1% chlorhexidine-poloxamer gel, the area of the full-thickness skin wounds decreased by an average of $12.1 \pm 12.0 \text{ mm}^2$ per day. The average wound area on the 10th day was 68.2% smaller than that on the 1st day of the experiment or 3.2% larger than that in rats of the I group and 17.5% ($p < 0.05$) smaller than that in rats of the V group. The average wound area on the 20th day was 29.2% smaller than that on the 10th day and 97.4% smaller than that on the 1st day of the experiment. On the 20th day of experiment, the average wound area in rats of the IV group was 0.8% larger than that in rats of the I group ($p < 0.05$) and 6.3% smaller than that in rats of the V group ($p < 0.05$) (Fig. 2). Complete epithelisation of wounds in rats of the III group was observed on 25th day of the experiment.

Sutured wound model. Threads were not removed because it was planned to achieve a complete healing of wounds at the end point of the experiment. Sutures of skin wounds were strong and did not dehiscence during all the time of the experiment. Signs of surface infection were observed in all rats of the I group and in three animals of the V group.

Sutured skin in rats of the II group thinned by the average of $0.2 \pm 0.3 \text{ mm}$ per day. The maximum thickness of sutured skin in rats of the II group was assessed on the 2nd day of the experiment and was 60.6% higher than that on the 1st day of the experiment. The skin was 10.8% thinner than in rats of the I group, and 36.4% thicker than in rats of the V group where 0.25% chlorhexidine-poloxamer gel was used. Threads fell from the wounds on the 8th day and the skin was 4.8% thicker than on the 1st day of the ex-

periment. Threads in rats of the II group fell at the same day compared with rats of the I group, and threads in the rats of the V group fell 3 days later.

The sutured skin in rats of the III group thinned by the average of $0.3 \pm 0.2 \text{ mm}$ per day. The maximum thickness of the sutured skin in rats of the III group was assessed on the 2nd day of the experiment and was 55.6% thicker than on the first day of the experiment. Skin was 2.7% thinner than in rats of the I group and 41.7% thicker than in rats of the V group using 0.5% chlorhexidine-poloxamer gel. Threads fell from the wounds on the 8th day and the thickness of the skin was the same as on the first day of the experiment. Threads in rats of III groups fell at the same day compared with rats of the I group, and threads in the rats of the V group fell 3 days later.

The sutured skin in rats of the IV group thinned by the average $0.3 \pm 0.1 \text{ mm}$ per day. The maximum thickness of the sutured skin in rats of the IV group was assessed on the 2nd day of the experiment and was 56.8% thicker than on the 1st day of the experiment. Skin thickness in rats of the IV group was the same as in the rats of the I group and 56.8% higher than that in rats of the V group where 1% chlorhexidine-poloxamer gel was used. Threads fell from the wounds on the 8th day and the skin was 4.5% thicker than on the 1st day of the experiment. Threads in rats of the IV group fell at the same day compared with rats of the I group, and threads in rats of the V group fell 3 days later.

Skin irritation. Chlorhexidine-poloxamer gels used on the non-haired skin did not induced any visible changes in the skin and discomfort for the animals during the experiment. The rats were found to be physically active and they were consuming food and water in a regular way.

Histopathological investigation. A view specific to a healing wound was observed in all histological specimens from all rats in excision and incision wound model groups. The newly formed collagen fibres were organized, rich granulation tissue with inflammatory mononuclear cells infiltration was observed, and the place of new scar was covered by hyperplastic epithelium. The surface of wounds was covered by completely formed squamous cell layer. No great differences were found between rats of different groups (Fig. 3). No changes were observed in the dermis or epidermis in histological specimens when chlorhexidine-poloxamer gel was applied to the healthy skin (skin irritation study).

The thickest epidermis of the completely healed non-sutured excision wounds was measured in rats of the IV group (respectively 17.3% and 16.8% thicker compared with rats of the I and V groups). The epidermis in rats of the II group was slightly thinner

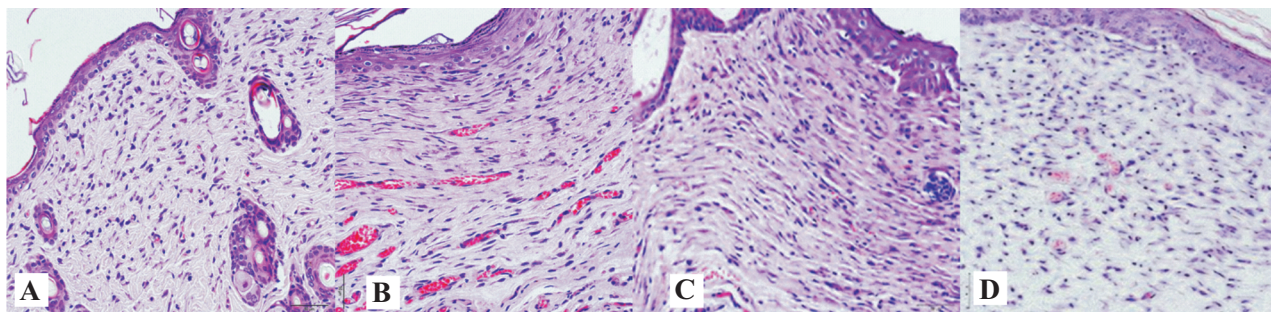


Fig. 3. A histological view of excision of a full-thickness non-sutured skin wound: A – 0.25% chlorhexidine-poloxamer gel; B – 0.5% chlorhexidine-poloxamer gel; C – 1.0% chlorhexidine-poloxamer gel; D – untreated wound (low magnification).

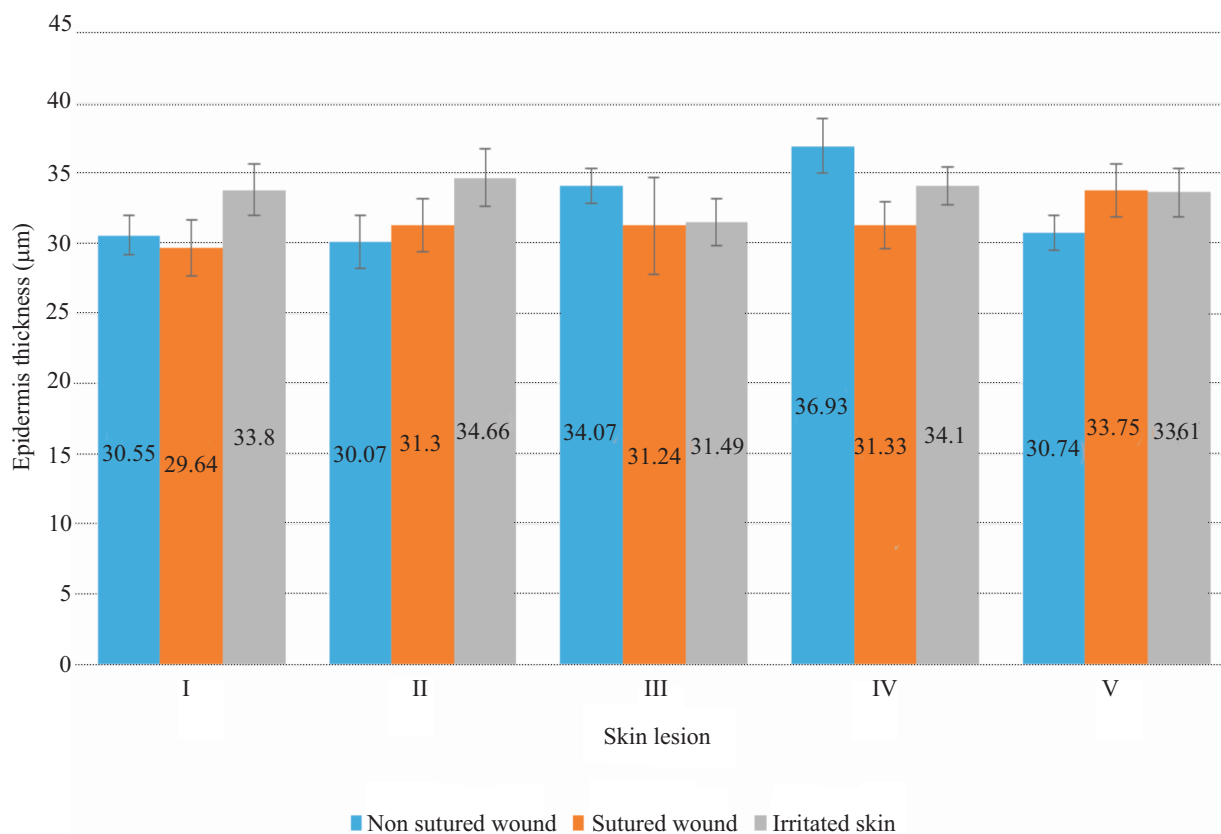


Fig. 4. The thickness of the epidermis after application of different concentrations of a chlorhexidine-poloxamer gel.

(respectively 10.3% and 9.8% thicker compared with rats of the I and V groups). Meanwhile, thickness of the epidermis of the III group rats was the same as that in the rats of the I and V groups (Fig. 4).

Epidermal thickness of completely healed sutured wounds was nearly the same in all the groups (31.29 ± 0.05 mm on average). Compared with the I and V groups of rats, thickness of the epidermis was respectively 5.3% thicker than that in the rats of the I group and 7.3% thinner than that in rats of the V the group.

Using chlorhexidine-poloxamer gel on the healthy skin, differences in thickness of the epidermis in rats in different groups were not significant different (Fig. 4).

Discussion

The healing of wounds is a dynamic process during which skin defect is restored. The healing rate depends on whether a tissue was lost during trauma or surgical procedure and on materials which are used for the wound care. The new granulation tissue needs to form during the process of wound healing because there is a certain tissue defect in full-thickness skin wound.

The present findings suggest that infected full-thickness non-sutured skin wounds were healed at different speed when different concentrations of antiseptic chlorhexidine-poloxamer gels were used. Any

signs of superficial infection were not seen in all rats using experimental gels on the skin wounds. Signs of a bacterial infection such as purulent plaque and fetid odor were determined in full-thickness infectious non-sutured skin wounds where one poloxamer were used or in untreated wounds.

A complete epithelization time of wound is important for the assessment of the process of wound healing. The present results revealed that full-thickness non-sutured skin wounds reached the quickest complete epithelization using a 0.5% chlorhexidine-poloxamer gel. The wound epithelization using one poloxamer lasted two days longer and in untreated wounds 7 days longer. The chlorhexidine does not inhibit the migration of platelets, macrophages, leukocytes, fibroblasts to the wound; therefore the chlorhexidine stimulates the healing of open wounds and reduce risk of recurrent infection (Kloos et al. 2013). After topical application, a poloxamer dries forming a thin protective film as it warms to body temperature. The good condition for the healing of wounds (appropriate humidity, protection from mechanical environmental factors) occurred using a chlorhexidine-poloxamer gel because the breathable film was formed on the surface of the wound (Dumortier et al. 2006). The present results and the data presented in the literature confirm that a chlorhexidine-poloxamer gel has a broad-spectrum antimicrobial effects (Odore et al. 2000, Vianna et al. 2004, Wannachaiyasit et al. 2010, Babickaitė et al. 2016). When fibroblasts are involved in the retraction process, the time for the full-thickness skin defect restoration is shorter. Even very low concentrations of a poloxamer 407 facilitate early collagen synthesis and microcirculation, increase attachment and growth of fibroblasts and may have applications in the early healing of post-surgical wounds (Dumortier et al. 2006).

Full-thickness sutured skin wounds are healed at the same speed using different concentrations of chlorhexidine-poloxamer gels. Signs of a bacterial infection were seen in wounds where one poloxamer was used, as well as in untreated wounds. Many studies have revealed that a chlorhexidine is not absorbed through the skin (Atiyeh et al. 2009), thus the active ingredient stays in the target tissue (on the surface of the wound). The present results revealed that the full-thickness sutured skin was thicker using antiseptic gel comparing with wounds where the gel was not applied. Absorption of chlorhexidine increases when either the *stratum corneum* is thin or the sub-clinical thinness of the *stratum corneum* occurs due to repeated frictions, even if the skin seems healthy (Calogiuri et al. 2013).

Chlorhexidine can induce allergic contact dermatitis at the site of application. Topical chlorhexidine may cause anaphylaxis, especially when applied on mucosal surfaces. Chlorhexidine can be responsible for hypersensitive reactions from contact dermatitis to life-threatening anaphylaxis. If allergic reaction is very acute, clinical signs of urticaria or even anaphylaxis can be observed. Reactions are more frequent if chlorhexidine solutions are used on mucosal surfaces, less often when chlorhexidine solutions are used on open wounds or healthy skin. Photosensibilisation is available too. As widely medicinal substance is spread as more frequently adverse reactions are seen (Calogiuri et al. 2013, Silvestri and McEnery-Stonelaki 2013, Moka et al. 2015). Skin irritation can also occur when poloxamer is used on its own. Usually local skin irritation is observed for a short time. The *stratum corneum* protects from skin irritation because it is the main barrier that does not let strong hydrophilic or lipophilic substances pass into deeper layers (Dumortier et al. 2006).

Chlorhexidine is more effective and causes less skin irritation compared with many antiseptic substances. No changes were observed in histological specimens of healthy skin using chlorhexidine-poloxamer gels. No systemic clinical signs were observed in rats, water and food consumption did not change. Chlorhexidine is widely used not only in human but also in veterinary medicine, because of its broad spectrum and low toxicity.

Topical dosage forms destined for administration onto the skin need to possess optimal mechanical properties (such as spreadability), bioadhesion (prolonged contact time at administration site), acceptable viscosity and possibly, predictable release of active ingredients. Topical dosage forms destined for administration onto the skin need to possess optimal bio adhesion (be able to provide close and prolonged contact between the formulation of medicine and affected skin area). An ideal wound dressing should not only have a positive effect on the healing of wounds but provide good functional and aesthetic characteristics too (Hurler et al. 2012). Chlorhexidine-poloxamer gels accelerate healing of infected skin wounds because the active ingredient chlorhexidine remains at the application site, systemic effects are avoided. Moreover, chlorhexidine-poloxamer gels are comfortable to use because they can be easily washed off from the wound surface by water. The present study revealed that chlorhexidine-poloxamer gels promote the healing of full-thickness skin wounds without skin irritation. This makes possibility for planning further experiments with target animal species.

References

- Akilandeswari S, Senthamarai R, Valarmathi R, Prema S (2010) Wound healing activity of *Sida acuta* in Rats. *Int J PharmTech Res* 2: 585-587.
- Atiyeh BS, Dibo SA, Hayek SN (2009) Wound cleansing, topical antiseptics and wound healing. *Int Wound J* 6: 420-430.
- Babickaitė L, Ramanauskienė K, Grigonis A, Ivaskienė M, Daunoras G, Klimienė I, Virgailis M, Zamokas G, Inkėnienė AM, Matusevičius AP (2016) Determination of antimicrobial activity of chlorhexidine gel. *Acta Polo Pharm Drug Res* 73: 1623-1630.
- Banovic F, Bozic F, Lemo N (2013) In vitro comparison of the effectiveness of polihexanide and chlorhexidine against canine isolates of *Staphylococcus pseudintermedius*, *Pseudomonas aeruginosa* and *Malassezia pachydermatis*. *Vet Dermatol* 24: 409-13.
- Calogiuri GF, Di Leo E, Trautmann A, Nettis E, Ferrannini A, Vacca A (2013) Chlorhexidine Hypersensitivity: A Critical and Updated Review. *J Allergy Ther* 4: 1-7.
- Carceles CM, Serrano JM, Marin P, Escudero E, Fernandez-Varon E (2006) Pharmacokinetics of Moxifloxacin in Rabbits After Intravenous, Subcutaneous and a Long-acting Poloxamer 407 Gel Formulation Administration. *J Vet Med A* 53: 300-304.
- D'Acampora AJ, Vieira DS, Silva MT, Farias DC, Tramonte R (2006) Morphological analysis of three wound-cleaning processes on potentially contaminated wounds in rats. *Acta Cir Bras* 21: 332-340.
- Dumortier G, Grossiord JL, Agnely F, Chaumeil JC (2006) A Review of Poloxamer 407 Pharmaceutical and Pharmacological Characteristics. *Pharm Res* 23: 2709-2728.
- Gailienė G (2011) Surgical Site Infections Associated with Health Care (II). *Lith Obst Gyn* 9: 206-212.
- Hurler J, Engesland A, Kermay BP, Basnet NS (2012) Improved Texture Analysis for Hydrogel Characterization: Gel Cohesiveness, Adhesiveness, and Hardness. *Appl Polym Sci* 125: 180-188.
- Kloos I, Straubinger RK, Werckenthin C, Mueller RS (2013) Residual antibacterial activity of dog hairs after therapy with antimicrobial shampoos. *Vet Dermatol* 24: 250-e54.
- Moka E, Argyra E, Siafaka I, Vadalouca A (2015) Chlorhexidine: Hypersensitivity and anaphylactic reactions in the perioperative setting. *J Anaesthesiol Clin Pharmacol* 31: 145-148.
- Nayak BS, Isitor G, Davis EM, Pillai GK (2007) The Evidence based wound healing activity of *Lawsonia inermis* Linn. *Phytother Res* 21: 827-831.
- Obermeier A, Schneider J, Wehner S, Matl FD, Schieker M, von Eisenhart-Rothe R, Stemberger A, Burgkart R (2014) Novel High Efficient Coatings for Anti-Microbial Surgical Sutures Using Chlorhexidine in Fatty Acid Slow-Release Carrier Systems. *PLoS One* 9: e101426.
- Odore R, C Valle V, Re G (2000) Efficacy of Chlorhexidine against Some Strains of Cultured and Clinically Isolated Microorganisms. *Vet Res Commun* 24: 229-238.
- Oryan A, Naeini AT, Nikahval B, Gorjian E (2010) Effect of aqueous extract of *Aloe vera* on experimental cutaneous wound healing in rat. *Vet Arhiv* 80: 509-522.
- Patel HR, Patel RP, Patel MM (2009) Poloxamers: A pharmaceutical excipients with therapeutic behaviors. *Int J PharmTech Res* 1: 299-303.
- Sabol F, Dancakova L, Gal P, Vasilenko T, Novotny M, Smetana K, Lenhardt L (2012) Immunohistological changes in skin wounds during the early periods of healing in a rat model. *Vet Med* 57: 77-82.
- Salami AA, Imosemi IO, Owoeye OO (2006) A Comparison of the Effect of Chlorhexidine, Tap Water and Normal Saline on Healing Wounds. *Int J Morphol* 24: 673-676.
- Scaffaro R, Botta L, Sanfilippo M, Gallo G, Palazzolo G, Puglia AM (2013) Combining in the melt physical and biological properties of poly(caprolactone) and chlorhexidine to obtain antimicrobial surgical monofilaments. *Appl Microbiol Biotechnol* 97: 99-109.
- Selvaraj N, Lakshmanan B, Mazumder PM, Karuppasamy M, Jena SS, Pattnaik AK (2011) Evaluation of the healing of wounds and antimicrobial potentials of *Ixora coccinea* root extract. *Asian Pac J Trop Med* 4: 959-963.
- Silvestri DL, McEnery-Stonelake M (2013) Chlorhexidine: uses and adverse reactions. *Dermatitis* 24: 112-118.
- Suresh J, Manish G, Anil B, Vimal A (2011) Skin Irritation Study of Intradermal Patch of Chitosan Containing Trazodone-HCl on Rat Skin. *Int J Res Pharm Biom Sci* 2: 1082-1084.
- Vianna ME, Gomes BP, Berber VB, Zaia AA, Ferraz CC, Souza-Filho FJ (2003) In vitro evaluation of the antimicrobial activity of chlorhexidine and sodium hypochlorite. *Oral Surg Oral Med Oral Pathol Oral Radiol Endod* 97: 79-84.
- Wannachaiyasit S, Phaechamud T (2010) Development of chlorhexidine thermosensitive gels as a mouth antiseptic. *JMMM* 3: 165-168.