

DOI 10.2478/v10181-011-0088-6

Original article

Root surface temperature rise of mandibular first molar during root canal filling with high-temperature thermoplasticized Gutta-Percha in the dog

M. Lipski¹, K. Woźniak², D. Lichota³, A. Nowicka³

¹ Department of Preclinical Conservative Dentistry and Preclinical Endodontics, Faculty of Medicine and Dentistry, Pomeranian Medical University of Szczecin, Powstańców Wlkp. 72, 70-111 Szczecin, Poland

² Department of Orthodontics, Faculty of Medicine and Dentistry, Pomeranian Medical University of Szczecin, Powstańców Wlkp. 72, 70-111 Szczecin, Poland

³ Department of Conservative Dentistry, Faculty of Medicine and Dentistry, Pomeranian Medical University of Szczecin, Powstańców Wlkp. 72, 70-111 Szczecin, Poland

Abstract

This in vitro study evaluated the temperature rise on the outer root surface of the mandibular first molar following root canal filling using the high-temperature, thermoplasticized, Gutta-Percha technique (HTTG) (BeeFill) in the dog. Twelve extracted dog mandibular first molars were used. After root canal preparation, the teeth were filled with thermoplasticized Gutta-Percha and root canal sealer. Temperature changes on the vestibular surfaces of the mesial and distal roots of mandibular first molars were measured using a thermal imaging camera. The results of this in vitro study showed that using HTTG to fill mandibular first molars in dogs produces a safe temperature rise on the root surface and, therefore, should not damage the periodontal ligament and/or surrounding tissues.

Key words: dog, root canal obturation, Gutta-Percha, temperature rise on the root surface

Introduction

Complete obturation of the root canal system with an inert filling material and the creation of a hermetic apical seal are the goals of successful endodontic treatment. Gutta-Percha is the most commonly used root canal obturation material because of its inertness, biocompatibility, and plasticity when warmed, and ease of removal for post or retreatment (Golden and Henet 1992, Hammad et al. 2009, Bładowski 2011).

Many Gutta-Percha obturation techniques are used to fill root canals in the dog, including single cone, lateral or vertical condensation and, more recently, thermoplasticized Gutta-Percha on the carrier (Thermafil), low-temperature thermoplasticized injected Gutta-Percha technique (LTGT), and high temperature thermoplasticized injected Gutta-Percha technique (HTGT) (Anthony 1991, Golden and Henet 1992, Clark 1995, Mendoza 2000, Ulbricht 2002, Lipski 2006a, Capik and Stvrtina 2008).

Obturation of the root canal by injection of Gutta-Percha, introduced by Yee et al. (1977), is among the newest available root canal obturation techniques. The most popular systems utilizing high thermoplasticized Gutta-Percha are the Obtura II/III (Obtura II/III, Obtura Spartan, Earth City, Missouri), Element Obturation Unit (Element Obturation Unit, Sybron Endo, Orange, California), E&Q, (E&Q, Meta Biomed, Chungbuk, Korea) or BeeFill (BeeFill, VDW, Munich, Germany).

By using these devices, the Gutta-Percha is heated to a minimum temperature of 160°C, delivered into the prepared tooth in conjunction with a root canal sealer, and condensed vertically within the root canal system.

Although tooth root tissues are poor thermal conductors (Brown 1970), filling the canal with heated Gutta-Percha may be responsible for the outer root surface temperature (Lipski 2006a). Eriksson and Albrektsson (1983) conducted a vital-microscopic study on temperature threshold levels for heat-induced bone tissue injury in rabbits. They found that heating bone tissue to 47°C for 1 minute caused bone remodeling and fat cell necrosis (Eriksson et al. 1982, Eriksson and Albrektsson 1983).

Several in vitro studies examined the temperature produced on the outer root surface of human teeth during the injection of high-temperature thermoplasticized Gutta-Percha into the root canal (Barkhordar et al. 1990, Weller and Koch 1995, Lee et al. 1998, Sweatman et al. 2001, Lipski 2006b). Sweatman et al. (2001) measured temperature changes on the outer root surface of incisors and canines and found temperature rises from 5.27°C to 6.23°C, and Barkhordar et al. (1990) found an in vitro maximum mean temperature rise of 4.72°C using canines. In another in vitro study, Lipski (2006b) measured the outer root surface temperature rise on the mandibular and maxillary incisors and found the average increase values to be 5.98°C and 9.57°C, respectively.

The aim of this in vitro study was to measure the temperature changes on the outer root surfaces of mandibular first molars in the dog with infrared thermography following the injection of Gutta-Percha heated to 160°C (BeeFill).

Materials and Methods

Twelve mandibular first molar teeth extracted for periodontal reasons or obtained from adult canine cadavers were used in this study. All teeth were microscopically inspected to identify any defects or root fractures.

After access cavities were prepared and the contents of the pulp canal space were removed, a 10 K file was introduced into the canal until resistance was noted. Subsequently, the instrument was removed from the canal and the determined length was compared with the actual length of the tooth. If the measurement was approximately 2 mm shorter than the actual tooth length, it was considered as the working length. The canals were enlarged apically to size 40 (7 mesial canals and 5 distal canals), 45 (3 mesial canals and 4 distal canals), and 50 (2 mesial canals and 3 distal canals) using a K file (K file, VDW, Munich, Germany). The apical one-third was flared using the step-back technique and the middle and coronal two-thirds were shaped with sizes 2 through 4 Gates-Glidden drills (Gates-Glidden drill, VDW, Munich, Germany). The canals were irrigated with 2 ml of 1% sodium hypochlorite solution after use of each instrument, and dried with paper points.

The BeeFill system was prepared according to the manufacturer's instructions (BeeFill Operator's Manual, 1993). The working temperature was adjusted to 160°C. A 23-gauge needle from the BeeFill delivery system was placed within 3 mm of the prepared apical stop, and the Gutta-Percha was expressed. When back pressure was felt, the needle was withdrawn and the hand plugger (Hand plugger, Roeko, Langenau, Germany) was used to apply firm apical pressure to the Gutta-Percha. The remaining root canal space was back filled until Gutta-Percha was observed in the orifice, then compacted with a hand plugger to finish the obturation.

To obtain root canal obturation and temperature measurement, the crowns of the teeth were fixed with the entire root surface exposed to the air. Temperature changes were recorded on the whole of the mesial root surfaces during root canal obturation using a ThermoCam SC500 thermal imaging camera (ThermoCam SC500 thermal imaging camera, Flir, Danderyd, Sweden) and its dedicated software package. The camera was mounted on a stand perpendicular to the root surface and 15 cm away. The thermograms were recorded at 2-s intervals over a period of 60 s. The experiment was carried out under controlled environmental conditions ($T_a = 21 \pm 0.6^\circ\text{C}$, $RH = 50 \pm 5\%$, air flow < 0.5 m/s). The camera was calibrated for distance, ambient temperature, and emissivity of the root tissue. The emissivity of the root tissues was calculated to be 0.91.

Results

The mean temperature rise recorded on the outer root surfaces of the mesial roots was $6.64 \pm 2.43^\circ\text{C}$

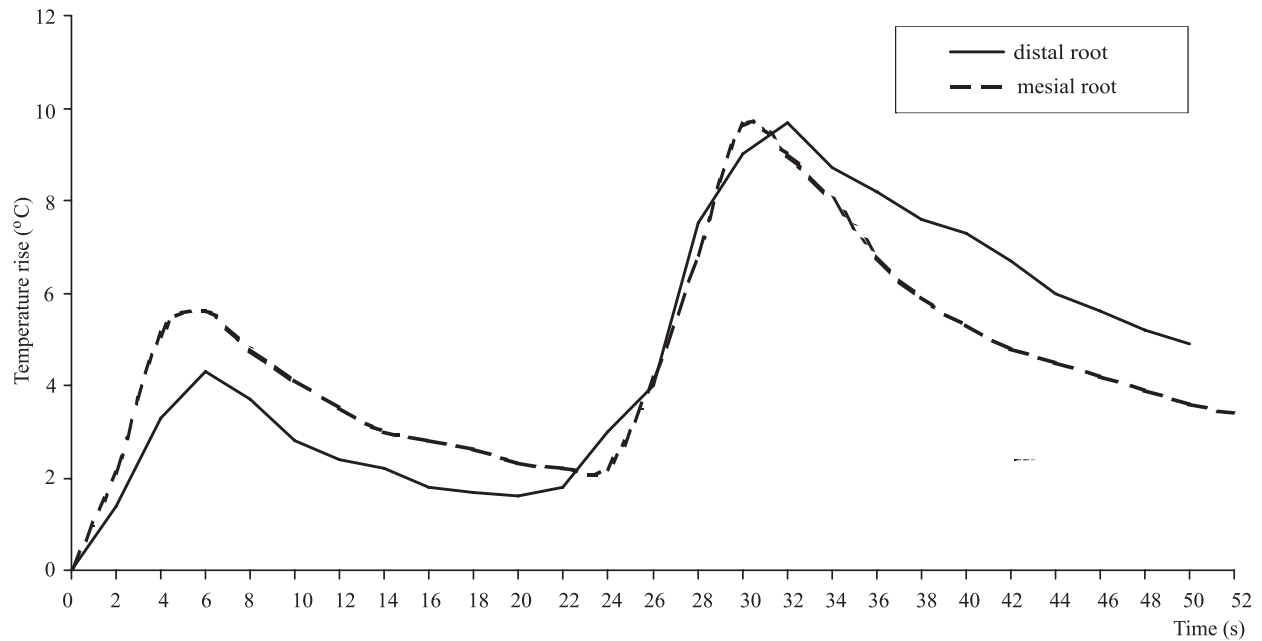


Fig. 1. Temperature changes over time on the outer root surfaces of selected teeth during root canal filling using the BeeFill system.

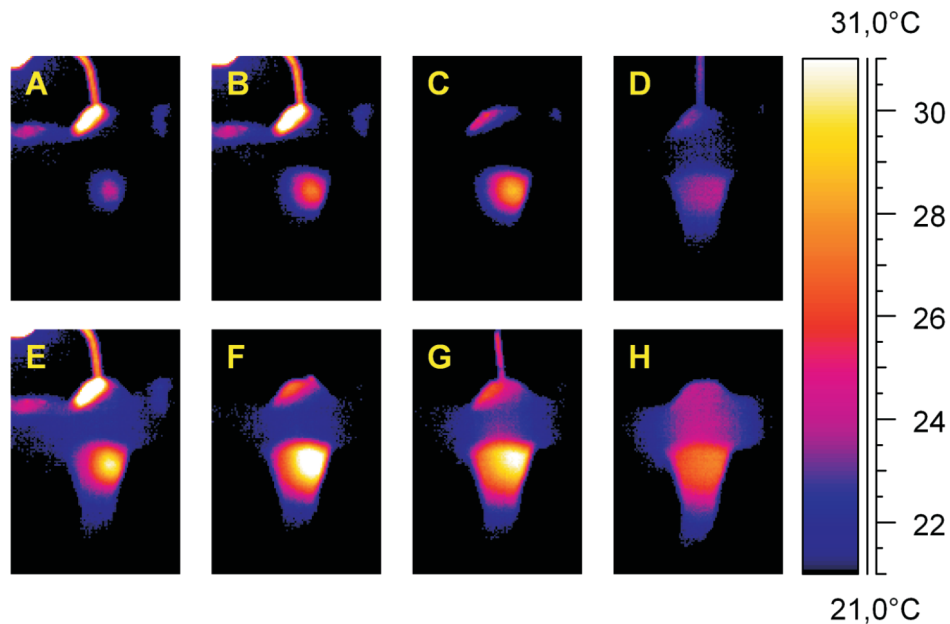


Fig. 2. Thermograms recorded during root canal filling using the BeeFill system. Thermal images of the surface of the mesial root of a mandibular first molar were recorded (A, B) during the injection of heated Gutta-Percha into the root canal, (C) directly after needle removal, (D) during vertical compaction using a hand plugger, (E) during a second injection of the Gutta-Percha into the root canal space, (F) directly after needle removal, (G) during compaction using a hand plugger, and (H) directly after completion of compaction.

(7.0-10.8°C) and of the distal roots was $6.12 \pm 2.23^\circ\text{C}$ (3.1-9.7°C) (no significant difference; Mann-Whitney U test, $p < 0.05$).

Figure 1 shows the temperature fluctuation on the mesial and distal roots. The injection of heated

Gutta-Percha into the root canal produced two peak temperature elevations; first, a lower elevation of 5.6°C and 4.3°C, respectively, after introduction of the Gutta-Percha into the apical part of the root canals, and second a higher elevation of 9.6°C and 9.7°C, re-

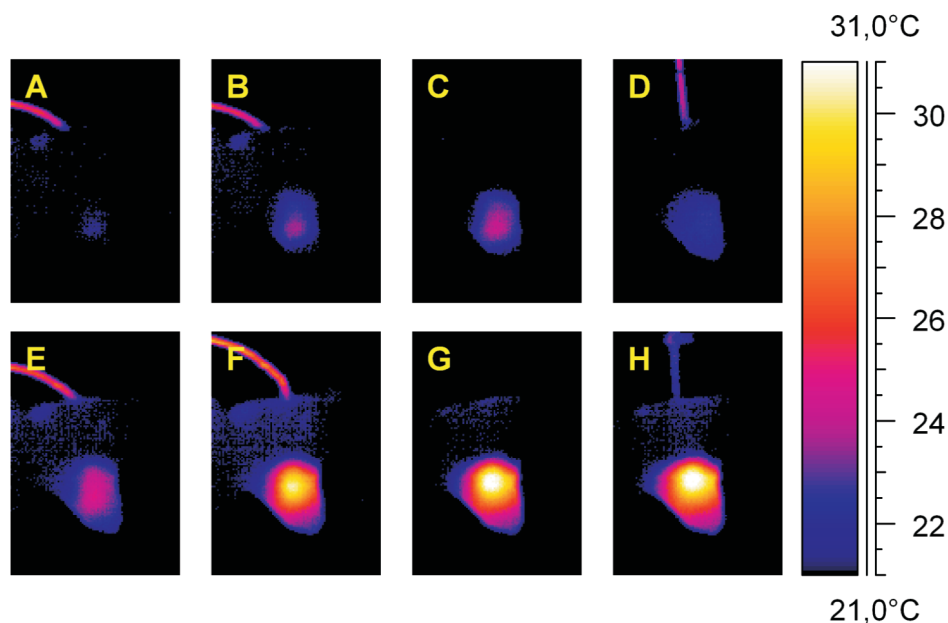


Fig. 3. Thermograms recorded during root canal filling using the BeeFill system. Thermal images of the surface of the distal root of a mandibular first molar were recorded (A, B) during injection of the heated Gutta-Percha into the root canal, (C) directly after needle removal, (D) during vertical compaction using a hand plugger, (E, F) during a second injection of the Gutta-Percha into the root canal space, (G) directly after needle removal, and (H) during compaction using a hand plugger.

spectively, after injection into the middle and coronal parts. After this, relatively slow decreases in temperature were recorded.

Figures 2 and 3 represent thermograms of the vestibular surface of the mesial and distal roots of the representative mandibular molar recorded during the root canal obturation.

Discussion

It is generally accepted that a temperature rise higher than 10°C, when transmitted to the outer root surface, could be responsible for damage to the cement, periodontal ligament, and alveolar bone. However, Rouiller and Majno (1953) described hard tissue injury after heating the rabbit metatarsal or radial bone to 55°C, and Sellius and Cohen (1991) showed that hyperthermia of >6°C for 1 h causes apoptosis of thymocytes. Other long-term studies on cultured cells showed that osteoblasts are more sensitive to heat than chondrocytes when exposed to a temperature increase of 4°C for 4 days (Fluor et al. 1992).

In this *in vitro* study, the temperature rises generated by filling root canals with Gutta-Percha heated to 160°C ranged between 3.1°C and 10.8°C. Although the critical temperature was exceeded in two cases, no surrounding tissue damage is to be expected. This is because the values were recorded *in vitro*, so the

increase would be significantly lower with the cooling effect of the surrounding tissues and circulation. This was confirmed by an *in vivo* study in cats, where procedures generating *in vitro* temperature increases ranging from 12.8°C to 28.8°C (mean 22.3°C), when used in clinical experiments, did not produce irreversible damage to the tissue surrounding the canine. In the cited study, periodontal tissues were histologically assessed 35 days after the procedure (Lipski 2007).

The safety of the injection technique was proven in an *in vivo* study in mongrel dogs by Gutman et al. (1987), who showed no apparent periodontal tissue destruction after the injection of high-temperature, thermoplasticized Gutta-Percha (Obtura, 160°C) into the root canal. In the study cited, the temperature changes on the external surface of the bone overlying the roots obturated with thermoplasticized Gutta-Percha were also recorded, and the maximum temperature elevation over 60 s was found to be 1.1°C. In another *in vivo* study, Molywdas et al. (1989) used two beagle dogs to assess periodontal reactions following root canal filling using the same system. The obturation with Gutta-Percha heated to 160°C caused an inflammatory reaction and destruction of collagen fibers in the area around the apical foramen. The alveolar founding bone, the roots of the teeth, and the periodontal ligament at the side of the root surface remained normal. During the ob-

turation procedure, no temperature measurements were taken in the periodontal ligament or on the bone overlying the roots.

Temperature increase on the root canal surface might also be influenced by the temperature of the Gutta-Percha injected into the canal. When filling the canal in human teeth with thermoplasticized Gutta-Percha at different temperatures, Weller et al. (1995) observed that the temperature on the surface of the tooth was significantly higher after injection of 185°C- and 200°C-heated Gutta-Percha compared with the 160°C mass. In this study, the Gutta-Percha was heated to only 160°C because the short filling time enabled by the automatic BeeFill application did not require higher plasticity.

In conclusion, the temperature rises recorded on the outer root surface of mandibular first molars in dogs are relatively low. From this in vitro study, no evidence was found indicating that the BeeFill obturation system (Gutta-Percha heated to 160°C) would result in damage to the cement, periodontal ligament, and/or alveolar bone as a consequence of the temperature rise on the outer root surface of these teeth.

References

- Anthony JM (1991) Comparative obturation techniques in the canine. *J Vet Dent* 8: 24-29.
- Barkhordar RA, Goodis HE, Watanabe L, Koumdjian J (1990) Evaluation of temperature rise on the outer surface of teeth during root canal obturation techniques. *Quintessence Int* 21: 585-588.
- Bładowski M, Kotowicz-Gears A, Wojtkiewicz J (2011) Restoration of fractured canines in ferrets after one-step root canal treatment. *Pol J Vet Sci* 14: 137-139.
- Brown WS, Dewey WA, Jacobs HR (1970) Thermal properties of teeth. *J Dent Res* 49: 752-755.
- Capik I, Štvrtina S (2008) Comparison of gutta-percha obturation techniques in the treatment of wide root canals in dogs. *Acta Vet Brno* 77: 291-296.
- Clarke DE (1995) Endodontics of dogs and cats: an alternative to extraction. *Aust Vet J* 72: 383-389.
- Eriksson A, Albrektsson T, Grane B, McQueen D (1982) Thermal injury to bone. A vital-microscopic description of heat effects. *Int J Oral Surg* 11: 115-121.
- Eriksson AR, Albrektsson T (1983) Temperature threshold levels for heat-induced bone tissue injury: a vital-microscopic study in the rabbit. *J Prosthet Dent* 50: 101-107.
- Flour MP, Ronot X, Vincent F, Benoit B, Adolphe M (1992) Differential temperature sensitivity of cultured cells from cartilaginous or bone origin. *Biol Cell* 75: 83-87.
- Golden AL, Hennet PR (1992) Root canal obturation using Thermafil endodontic obturators in dog teeth. *J Vet Dent* 9: 4-7.
- Gutmann JL, Rakusin H, Powe R, Bowles WH (1987) Evaluation of heat during root canal obturation with thermoplasticized gutta-percha. Part II. In vivo response to heat levels generated. *J Endod* 13: 441-448.
- Hammad M, Qualtrough A, Silikas N (2009) Evaluation of root canal obturation: a three-dimensional in vitro study. *J Endod* 35: 541-544.
- Lee FS, Van Cura JE, BeGole E (1998) A comparison of root surface temperatures using different obturation heat sources. *J Endod* 24: 617-620.
- Lipski M (2006a) In vitro infrared thermographic assessment of root surface temperatures generated by high-temperature thermoplasticized injectable gutta-percha obturation technique. *J Endod* 32: 438-441.
- Lipski M (2006b) Root surface temperature rise in cats canine teeth during root canal filling using the Thermafil Plus technique. *Med Weter* 62: 1284-1287.
- Lipski M (2007) An in vitro and an in vivo study of root surface temperature change during root canal obturation with thermoplasticized gutta-percha. *Ann Acad Med Stetin Supl* 111.
- Mendoza KA, Manfra Marretta S, Siegel AM, Stapleton BL, Wiggs RB, Klippert LS (2002) Comparison of two heated gutta percha and sealer obturation techniques in canine teeth in dogs. *J Vet Dent* 17: 69-74.
- Molyvdas I, Zervas P, Lambrianidis T, Veis A (1989) Periodontal tissue reactions following root canal obturation with an injection-thermoplasticized gutta-percha technique. *Endod Dent Traumatol* 5: 32-37.
- Rouiller C, Majno G (1953) Morphologische und chemische Untersuchungen an Knochen nach Hitzeeinwirkung. *Beitr Path Anat* 113: 100-104. .
- Sellins KS, Cohen JJ (1991) Hyperthermia induces apoptosis in thymocytes. *Radiat Res* 126: 88-95.
- Sweatman TL, Baumgartner JC, Sakaguchi RL (2001) Radicular temperatures associated with thermoplasticized gutta-percha. *J Endod* 27: 512-515.
- Ulbricht RD, Marretta SM, Baker GJ, Siegel AM, Klippert LS (2002) Comparison of two heated gutta-percha obturation techniques of the mandibular first molar in the dog. *J Vet Dent* 19: 63-70.
- Weller RN, Koch KA (1995) In vitro radicular temperatures produced by injectable thermoplasticized gutta-percha. *Int Endod J* 28: 86-90.
- Yee FS, Marlin J, Krakow AA, Gron P (1997) Three-dimensional obturation of the root canal using injection-molded, thermoplasticized dental gutta-percha. *J Endod* 3: 168-174.