

DOI 10.24425/pjvs.2025.156065

Original article

Correlation between the Mitral INsufficiency Echocardiographic score and radiographic variables in dogs with myxomatous mitral valve disease

J. Lee¹, M. Kim¹, H. Kim², J. Ryu³, T. Oh¹, S. Bae¹

¹Department of Veterinary Internal medicine, College of Veterinary Medicine, Kyungpook National University, 80 Daehak-ro, Daegu, 41566, Republic of Korea

²Bone Animal Medical Hospital, 2545 Dalgubeol-daero, Daegu, 42056, Republic of Korea

³One-health Animal Hospital, 23Bukbusunhwan-doro, Ulsan, 44629, Republic of Korea

Correspondence to: S. Bae, e-mail: sgbac@knu.ac.kr

Abstract

Myxomatous mitral valve disease (MMVD) in dogs can progress gradually with left atrial enlargement. In veterinary medicine, several radiographic variables including the vertebral heart size (VHS), vertebral left atrial size (VLAS), modified VLAS (M-VLAS), and radiographic left atrial dimension (RLAD) are used to assess cardiac enlargement. The Mitral INsufficiency Echocardiographic (MINE) score, which provides an echocardiographic assessment of the severity of MMVD, has recently been used as a predictor of cardiac death. This study aimed to evaluate the correlation and cut-off values between the MINE score and radiographic variables.

A total of 132 dogs with MMVD were recruited. The correlation between radiographic variables and the MINE score was assessed using Pearson's correlation analysis. Receiver operating characteristic (ROC) curves and the corresponding area under the curve (AUC) values and 95% confidence intervals (CIs) were generated for radiographic variables using a MINE score over 8 (severe) as the classifiers.

The MINE score showed a positive correlation with the VHS, VLAS, M-VLAS, and RLAD. For a cut-off MINE score ≥ 8 (severe), the radiographic variables could be ranked from highest to lowest AUC value as follows: VHS, VLAS, M-VLAS, and RLAD with cut-off values of 10.75, 2.75, 4.05, and 2.45, respectively.

The results of this study highlight the potential of thoracic radiography as an alternative method for providing valuable prognostic insights in dogs with MMVD.

Keywords: dogs, echocardiography, MINE score, MMVD, RLAD, VHS



Introduction

Mitral insufficiency, particularly myxomatous mitral valve disease (MMVD) is the most commonly acquired cardiac disease in dogs, accounting for approximately 75% of cases of heart disease, and is common in small breeds (Buchanan 1977, Olsen et al. 1999, Madsen et al. 2011). This disease typically progresses slowly; however, at times, the rate of progression can be unpredictable (Keene et al. 2019).

The Mitral INSufficiency Echocardiographic (MINE) score is an echocardiographic classification of the severity of MMVD based on four routinely acquired parameters and has been demonstrated to be clinically effective as it is associated with survival (Vezzosi et al. 2021).

However, echocardiographic assessment is not always a practical option due to its limited availability and high cost as well as the training and expertise necessary to acquire and interpret echocardiographic assessments. It can also be time consuming, and some patients cannot lie in recumbency without sedation. On the other hand, thoracic radiography is cost-effective and widely available. On thoracic radiographs, the vertebral heart size (VHS), vertebral left atrial size (VLAS), modified VLAS (M-VLAS), and radiographic left atrial dimension (RLAD) are routinely used parameters to assess cardiac enlargement.

In this study, we assessed the correlations of the VHS, VLAS, M-VLAS, and RLAD with the MINE score to evaluate the potential of thoracic radiographic assessment as an alternative method to predict the prognosis in dogs with MMVD. In addition, we obtained the cut-off values of these radiographic parameters for the severe and late stages of MMVD according to the MINE score.

Materials and Methods

Animals

This was a retrospective study; therefore, no institutional animal care and use approval was required. Dogs were included based on the following criteria: >3 years of age, body weight < 10 kg, echocardiographic evidence of MMVD defined as characteristic thickening and prolapse of the mitral valve leaflets and mitral valve regurgitation on color Doppler, and a fractional shortening (FS) >30%.

Dogs with other cardiac diseases including cardiac tumors, chamber dilation or concentric hypertrophy, chordae tendinae rupture, atrial fibrillation, patent ductus arteriosus, and atrial septal defects were excluded. In addition, dogs with other concurrent systemic diseases including hormonal disease and systemic hyperten-

sion were excluded. To accurately assess heart size, dogs with a history of taking cardiac medication or receiving parenteral fluid therapy at the time of enrollment were also excluded. Finally, to accurately measure the heart size, patients whose thoracic radiographs were misplaced and those with vertebral deformities were also excluded.

All dogs underwent a complete physical examination, thoracic radiography, and echocardiography. Data regarding breed, sex, age, body weight, American College of Veterinary Internal Medicine (ACVIM) stage, echocardiographic variables, and radiographic variables were obtained from the case records.

Data recording and analysis

Echocardiographic examinations were performed by graduates from the department of veterinary diagnostic imaging or operators under the supervision of a professor of veterinary diagnostic imaging. To determine the MINE score, the left atrial-to-aortic root ratio (LA/Ao), left ventricular end-diastolic diameter normalized for body weight (LVIDDn), left ventricular FS, and E-wave transmitral peak velocity (E-vel) were obtained according to their respective published methods. The stage was classified as mild, moderate, severe, or late by summing the scores of all the assessed items. According to the MINE score, a total score of 4-5 is considered to indicate mild disease. Total MINE scores of 6-7, 8-12, and 13-14 are classified as moderate, severe, and late-stage disease, respectively (Vezzosi et al. 2021).

Radiographic variables (the VHS, RLAD, VLAS, and M-VLAS) were measured by one observer. The measurement methods for the VHS, VLAS, M-VLAS, RLAD on lateral radiographic views were based on those described in previous studies, and the measurement value was defined as the length of the second line expressed in vertebral body units to the nearest 0.1 vertebra (Malcolm et al. 2018, Lam et al. 2018, Sánchez Salguero et al. 2018). All dogs included in this study had a typical thoracic conformation, without any markedly broad or narrow chests.

Statistical analysis

Statistical analyses were performed using commercial statistical software (SPSS Statistics v. 27, IBM, Somers, NY). A p -value ≤ 0.01 was considered significant for all analyses. The correlation of the MINE score with the M-VLAS, VLAS, VHS, and RLAD was assessed using Pearson's correlation analysis. Receiver operating characteristic (ROC) curves and the corresponding area under the curve (AUC) values and 95% confidence intervals (CIs) were generated for the VHS,

Table 1. Patient dogs characteristics according to the Mitral INsufficiency Echocardiographic (MINE) score.

	Mild (score 4-5) (n=37)	Moderate (score 6-7) (n=57)	Severe (score 8-12) (n=38)
Age (years)	10.87±3.21	11.38±2.9	11.43±2.1
Weight (kg)	4.2 (1.4–9)	4.25 (1.58–11.8)	4.05 (2.26–15)
Sex (CM/SF/M/F)	24/12/0/1	28/25/3/1	19/3/4/12

CM – Castrated male, SF – Spayed female, M – Male, F – Female

Table 2. Radiographic and echocardiographic variables and correlations with the MINE score in patient dogs.

	Mild (score 4-5) (n=37)	Moderate (score 6-7) (n=57)	Severe (score 8-12) (n=38)	Correlation with MINE score
VHS	10.5 (8.7–12.1)	10.4 (8.6–11.6)	11.5 (9.8–15)	0.573*
VLAS	2.2 (1.8–3.1)	2.3 (1.4–3.1)	2.9 (1.9–4.1)	0.574*
M-VLAS	3.4 (1.3–5)	3.4 (2.3–5.5)	4.4 (1.2–6.3)	0.486*
RLAD	2 (1.3–2.9)	2.3 (1.2–3)	2.5 (1.2–4.3)	0.506*

VHS – vertebral heart size, VLAS – vertebral left atrial size, M-VLAS – modified vertebral left atrial size, RLAD – radiographic left atrial dimension, MINE score, Mitral INsufficiency Echocardiographic score, * $p \leq 0.01$

VLAS, M-VLAS, and RLAD using MINE scores ≥ 8 (severe and late-stage disease) and 13 (late-stage disease) as the classifiers. The sensitivity and specificity of the VHS, VLAS, M-VLAS, and RLAD were determined with the Youden index to determine the optimal cut-off values of these radiographic parameters.

The Pearson correlation analysis yields a value between -1 and 1, and a correlation coefficient of 0 indicates that no linear relationship exists between two continuous variables, whereas a correlation coefficient of -1 or +1 indicates a perfect linear relationship. The size of Pearson's correlation coefficient is negligibly low when it is 0-0.3, low when it is 0.3-0.5, moderate when it is 0.5-0.7, and high when it is 0.7-0.9. Finally, a correlation coefficient of 0.9-1.0 indicates a very high correlation (Mukaka 2012).

For an AUC = 0.5, the test is not informative; for an AUC > 0.5 but ≤ 0.7 , the test is inaccurate; for an AUC > 0.7 but ≤ 0.9 , the test is moderately accurate; for an AUC > 0.9 but < 1.0, the test is highly accurate; and an AUC = 1, indicates a perfect test (Hanley et al. 1982, Swets 1988).

Results

A total of 132 dogs with MMVD were included in this study, and the distribution of the samples satisfied normality according to the central limit theorem (Kwak and Kim 2017). The average age was 11.25 years (range, 3.08-16.75), and the median body weight was 4.68 kg (range, 1.4-15 kg). Most dogs were Maltese

(n=47), followed by Pomeranians (n=28), Poodles (n=17), Mongrels (n=11), Shih Tzus (n= 8), Chihuahuas (n=5), Yorkshire Terriers (n=4), Schnauzers (n=4), and Cocker Spaniels (n=2). The remaining six dogs were of six other breeds (Jack Russel Terrier, Dachshund, Spitz, Bichon frisé, Lhasa Apso, Cavalier king Charles Spaniel). According to the MINE score classification, 37 dogs had mild disease, 57 dogs had moderate disease, 38 dogs had severe disease. The characteristics according to the MINE score are reported in Table 1.

The median VHS, VLAS, M-VLAS, and RLAD for each MINE score stage of disease increased as the stage of disease worsened (Table 2). The MINE score was positively correlated with the VHS ($r=0.573$, $p \leq 0.01$), VLAS ($r=0.574$, $p \leq 0.01$), M-VLAS ($r=0.486$, $p \leq 0.01$), and RLAD ($r=0.506$, $p \leq 0.01$) (Table 3). The ROC curve analyses indicated that all radiographic methods were useful in identifying dogs with severe disease (Table 4, Fig. 1) according to the MINE score.

Discussion

In Small breed dogs, the prevalence of MMVD increases significantly with age, and by the age of 13 years, up to 85% of these dogs exhibit evidence of MMVD (Buchanan 1977). In this study, the average patient age was 11.25 years, and the majority were senior dogs. The most common breeds were Maltese, Pomeranians, and Poodles, and the majority of the patients were small breed dogs weighing less than 5 kg.

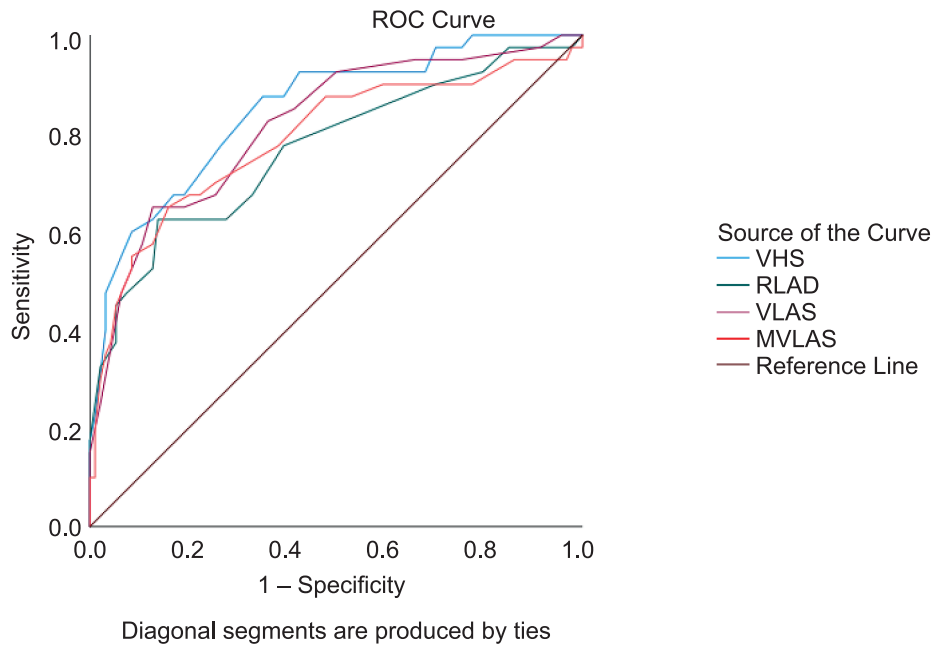


Fig. 1. Receiver-operating characteristic curve for radiographic variables for a MINE score over 8 in patient dogs.

VHS – vertebral heart size, VLAS – vertebral left atrial size, M-VLAS – modified vertebral left atrial size, RLAD – radiographic left atrial dimension.

Table 3. Cut-off values of radiographic variables for a MINE score over 8 in patient dogs.

Test result variables	AUC	SE	p	Cut-off	Sensitivity	Specificity	95% CI	
							Lower bound	Upper bound
VHS	0.848	0.037	0.000	10.75	0.88	0.65	0.776	0.920
VLAS	0.817	0.041	0.000	2.75	0.65	0.87	0.737	0.898
M-VLAS	0.789	0.048	0.000	4.05	0.65	0.84	0.696	0.882
RLAD	0.768	0.048	0.000	2.45	0.63	0.86	0.674	0.862

VHS – vertebral heart size, VLAS – vertebral left atrial size, M-VLAS – modified vertebral left atrial size, RLAD – radiographic left atrial dimension, MINE score, Mitral INSufficiency Echocardiographic score, AUC – area under the curve, SE – standard error, p – p-value, CI – confidence interval.

In previous studies, no direct comparisons have been made between the MINE score and cardiac size as determined by thoracic radiographic variables. However, some studies have explored the relationships between thoracic radiographic variables and left atrial enlargement (Malcolm et al. 2018, Sánchez Salguero et al. 2018, Bagardi et al. 2021, Lam et al. 2021, Vezzosi et al. 2021) as well as MMVD stages B2 or C (Levicar et al. 2022). Since the MINE score includes a component related to the degree of left atrial enlargement, it was expected that our study would identify similar trends to the findings of previous studies.

In our study, the correlation coefficients of the radiographic variables ranked from the highest to the lowest and the MINE were as follows: VLAS, VHS, M-VLAS, and RLAD. Interestingly, the VLAS and VHS showed nearly identical values. In contrast, a previous study (Lam et al. 2021) examining the cor-

relation between radiographic variables and left ventricular enlargement revealed the following order of correlations from highest to lowest: M-VLAS, VLAS, RLAD, and VHS. This trend was not in accordance with the findings of our study. The difference can be attributed to the fact that the MINE score encompasses not only left atrial enlargement but also other echocardiographic parameters (E-vel, LVIDDn, FS). As a result, the correlations in our study were lower. Moreover, the directional trends of these correlations also differed. In our study, the M-VLAS exhibited the lowest correlation with radiographic variables, whereas a prior study reported it as having the highest correlation. This discrepancy is likely due to the introduction of the vertebral body diameter in the dorsal aspect, leading to increased interobserver variability. Given the challenges associated with delineating the dorsal boundary of the left atrium and the potential for interob-

server differences, it is conceivable that the M-VLAS, similar to the RLAD, could yield varying measurements among different observers. The differing trends observed between this study and the study by Lam et al. may also be attributed to differences in the study subjects. In this study, the experimental group included small dogs weighing less than 5 kg, whereas the prior study included dogs weighing up to 20 kg.

In addition, we compared our results with those for different cut-off criteria used to distinguish between MMVD stages B and C (Levicar et al. 2022). While direct comparisons between these studies are challenging due to the varying conditions included, such as thoracic cavity shape differences between breeds, MMVD stages are assessed comprehensively, and left atrial enlargement as well as other variables were considered. Therefore, we expected that the correlation and cut-off values for MMVD stages B and C would be more similar to those for the MINE scores than to left atrial enlargement. In a previous study (Levicar et al. 2022), the cut-off values aimed at distinguishing between MMVD stages B and C using thoracic radiographic indicators were as follows: VHS (12.0, AUC: 0.75), VLAS (2.7, AUC: 0.78), and RLAD (2.3, AUC: 0.83). In another study (Lam et al. 2021), the cut-off values for left atrial enlargement were as follows: VHS (11.1, AUC: 0.9), VLAS (2.4, AUC: 0.95), M-VLAS (3.4, AUC: 0.97), and RLAD (1.7, AUC: 0.93). As anticipated, the cut-off values for the severe and late-stage disease according to the MINE score in this study were more similar to the cut-off values used to distinguish between MMVD stages B and C, with the exception of the VHS. Unlike the other indicators (VLAS, M-VLAS, RLAD), the VHS reflects the overall size of the heart rather than specific left atrial enlargement. This may explain why the VHS exhibited a different trend.

As MMVD progresses, the size of the heart increases gradually, and the patient may die in the late stages of the disease. Dogs with MMVD have traditionally been categorized by the ACVIM guidelines based on evidence of heart remodeling. However, many clinicians and owners want to know the stage of the disease as well as the prognosis or survival time for their dogs. A MINE score based on four echocardiographic variables can reflect the severity of mitral insufficiency and is associated with the survival time of patients with MMVD. One previous study showed significant differences in survival time for dogs with the same ACVIM stage but different MINE score classes. However, some dogs could not undergo echocardiography to obtain the MINE score for several reasons. In this regard, predicting the MINE score using chest radiography would be highly valuable in clinical veterinary medicine. There

are some studies that have explored the relationships of thoracic radiographic variables and left atrial enlargement with MMVD stages (Malcolm et al. 2018, Sánchez Salguero et al. 2018, Lam et al. 2021, Bagardi et al. 2021, Vezzosi et al. 2021, Levicar et al. 2022), but no direct comparisons have been made between the MINE score and cardiac size on thoracic radiographic variables. A distinctive aspect of this study is that the degree of association and cut-off values between the MINE score and thoracic radiographic heart size were determined. The cut-off values from this study are likely to be more useful for assessing patient prognoses, especially in situations in which echocardiography is not available. This underscores the potential clinical utility of the cut-off values derived in this study.

One limitation of this study is the uneven distribution of patients with MMVD across all stages of disease, which resulted in an insufficient number of samples for stages C and D. Also, Patients in the late stage were not included in the MINE score, and therefore a sample of patients at this stage is needed. This limitation can be attributed to the exclusion of patients with a history of medication intake to ensure accurate assessment of heart size, making it challenging to recruit patients with stages C and D MMVD (Woolley et al. 2007). If additional patients were recruited to form a more diverse population, more accurate results could be obtained.

References

- Bagardi M, Manfredi M, Zani DD, Brambilla PG, Locatelli C (2021) Interobserver variability of radiographic methods for the evaluation of left atrial size in dogs. *Vet Radiol Ultrasound*. 62: 161-174.
- Buchanan JW (1977) Chronic valvular disease (endocardiosis) in dogs. *Adv Vet Sci Comp Med*. 21: 75-106.
- Buchanan JW (2000) Vertebral scale system to measure heart size in radiographs. *Vet Clin North Am Small Anim Pract* 30: 379-393
- Cornell CC, Kittleson MD, Della Torre P, Häggström J, Lombard CW, Pedersen HD, Vollmar A, Wey A (2004) Allometric scaling of M-mode cardiac measurements in normal adult dogs. *J Vet Intern Med* 18: 311-321.
- Duler L, Visser LC, Jackson KN, Phillips KL, Pollard RE, Wanamaker MW (2021) Evaluation of radiographic predictors of left heart enlargement in dogs with known or suspected cardiovascular disease. *Vet Radiol Ultrasound* 62: 271-281.
- Hanley JA, McNeil BJ (1982) The meaning and use of the area under a receiver operating characteristic (ROC) curve. *Radiology* 143: 29-36.
- Hansson K, Häggström J, Kwart C, Lord P (2002) Left atrial to aortic root indices using two-dimensional and M-mode echocardiography in cavalier King Charles spaniels with and without left atrial enlargement. *Vet Radiol Ultrasound* 43: 568-575.

- Keene BW, Atkins CE, Bonagura JD, Fox PR, Häggström J, Fuentes VL, Oyama MA, Rush JE, Stepien R, Uechi M (2019) ACVIM consensus guidelines for the diagnosis and treatment of myxomatous mitral valve disease in dogs. *J Vet Intern Med* 33: 1127-1140.
- Kwak SG, Kim JH (2017) Central limit theorem: the cornerstone of modern statistics. *Korean J Anesthesiol* 70: 144-156.
- Lam C, Gavaghan BJ, Meyers FE (2021) Radiographic quantification of left atrial size in dogs with myxomatous mitral valve disease. *J Vet Intern Med* 35: 747-754.
- Levicar C, Granados-Soler JL, Freise F, Raue JF, Nolte I, Bach JP (2022) Comparison of different radiographic scores with associated echocardiographic measurements and prediction of heart enlargement in dogs with and without myxomatous mitral valve disease. *J Vet Cardiol* 44: 1-12.
- Madsen MB, Olsen LH, Häggström J, Höglund K, Ljungvall I, Falk T, Wess G, Stephenson H, Dukes-McEwan J, Chetboul V, Gouni V, Proschowsky HF, Cirera S, Karlskov-Mortensen P, Fredholm M (2011) Identification of 2 loci associated with development of myxomatous mitral valve disease in Cavalier King Charles Spaniels. *J Hered* 102 (Suppl 1): S62-S67.
- Malcolm EL, Visser LC, Phillips KL, Johnson LR (2018) Diagnostic value of vertebral left atrial size as determined from thoracic radiographs for assessment of left atrial size in dogs with myxomatous mitral valve disease. *J Am Vet Med Assoc* 253: 1038-1045.
- Mukaka MM (2012) Statistics corner: A guide to appropriate use of correlation coefficient in medical research. *Malawi Med J* 24: 69-71.
- Olsen LH, Mow T, Koch J, Pedersen HD (1999) Heart rate variability in young, clinically healthy Dachshunds: influence of sex, mitral valve prolapse status, sampling period and time of day. *J Vet Cardiol* 1: 7-16.
- Reinero C, Visser LC, Kellihan HB, Masseau I, Rozanski E, Clercx C, Williams K, Abbott J, Borgarelli M, Scansen BA (2020) ACVIM consensus statement guidelines for the diagnosis, classification, treatment, and monitoring of pulmonary hypertension in dogs. *J Vet Intern Med* 34: 549-573.
- Sánchez Salguero X, Prandi D, Llabrés-Díaz F, Manzanilla EG, Bussadori C (2018) A radiographic measurement of left atrial size in dogs. *Ir Vet J* 71: 25.
- Schober KE, Hart TM, Stern JA, Li X, Samii VF, Zekas LJ, Scansen BA, Bonagura JD (2010) Detection of congestive heart failure in dogs by Doppler echocardiography. *J Vet Intern Med* 24: 1358-1368.
- Swets JA (1988) Measuring the accuracy of diagnostic systems. *Science* 240: 1285-1293.
- Vezzosi T, Puccinelli C, Citi S, Tognetti R (2021) Two radiographic methods for assessing left atrial enlargement and cardiac remodeling in dogs with myxomatous mitral valve disease. *J Vet Cardiol* 34: 55-63.
- Vezzosi T, Grosso G, Tognetti R, Meucci V, Patata V, Marchesotti F, Domenech O (2021) The Mitral INSufficiency Echocardiographic score: A severity classification of myxomatous mitral valve disease in dogs. *J Vet Intern Med* 35: 1238-1244.
- Woolley R, Smith P, Munro E, Smith S, Swift S, Devine C, French A (2007) Effects of treatment type on vertebral heart size in dogs with myxomatous mitral valve disease. *Int J Appl Res Vet Med* 5: 43-48.